


Subcutaneous Migration: A Dynamic Anatomical Study of Gluteal Fat Grafting

Simeon Wall, Jr., M.D.
Daniel Delvecchio, M.D.
Steven Teitelbaum, M.D.
Nathaniel L. Villanueva,
M.D.
Erez Dayan, M.D.
Paul Durand, M.D.
Kyle Sanniec, M.D.
Rod J. Rohrich, M.D.

Shreveport, La.; Boston, Mass.; Santa
Monica, Calif.; and Dallas, Texas



Background: Recent anatomical studies have demonstrated that fat placed subjacent to the fascia of the gluteus maximus muscle can migrate deep through the muscle into the submuscular space, possibly causing tears in the gluteal veins, leading to fat embolisms. The purpose of this study was to define and to study subcutaneous migration and to determine whether fat placed in the subcutaneous space under a variety of pressures and fascial integrity scenarios can indeed migrate into the deep submuscular space.

Methods: Four hemibuttocks from two cadavers were used. Proxy fat was inserted using syringes with various fascia scenarios (1: fascia intact; 2: cannula perforations; 3: 6mm fascia defects) or using expansion vibration lipofilling (4: fascia intact). Subcutaneous pressures were recorded. After injections, anatomical dissections were performed to evaluate the migration of the proxy fat for each of the scenarios.

Results: Scenario 1: pressure reached approximately 125 to 150 mmHg and then plateaued and all the proxy fat remained in the subcutaneous space. Scenario 2: pressure reached a 199-mmHg plateau and no proxy fat spread deeper into the muscle or beneath it. Scenario 3: pressure gradually rose to 50 mmHg then fell again and the submuscular space contained a significant amount of proxy fat. Scenario 4: pressure rose to a maximum of 30 mmHg and all of the proxy fat remained in the subcutaneous space.

Conclusions: The gluteus maximus fascia is a stout wall that sets up the dangerous condition of deep intramuscular migration with subfascial injections and the protective condition of subcutaneous migration with suprafascial injections. These persuasive findings are profound enough to propose a new standard of care: no subfascial or intramuscular injection should be performed, and all injections should be performed exclusively into the subcutaneous tissue. (*Plast. Reconstr. Surg.* 143: 1343, 2019.)

Gluteal fat grafting is a rapidly growing procedure, having an annualized growth rate of 24 percent over the past 3 years.¹ Despite this, its safety profile has been questioned, with increased awareness of fatal pulmonary fat embolism, heralded by the sentinel article by Cárdenas-Camarena et al.²

Recent anatomical studies have demonstrated that fat placed subjacent to the fascia of the gluteus maximus muscle can migrate deep through the muscle into the submuscular space. We

defined this phenomenon as deep intramuscular migration. Because of the fragile nature of the gluteal veins, their short length, and their fixed

Supplemental digital content is available for this article. Direct URL citations appear in the text; simply type the URL address into any Web browser to access this content. Clickable links to the material are provided in the HTML text of this article on the *Journal's* website (www.PRSJournal.com).

A “Hot Topic Video” by Editor-in-Chief Rod J. Rohrich, M.D., accompanies this article. Go to PRSJJournal.com and click on “Plastic Surgery Hot Topics” in the “Digital Media” tab to watch.

From The Wall Center for Plastic Surgery; Back Bay Plastic Surgery; private practice; the Department of Plastic Surgery, University of Texas Southwestern Medical Center; and the Dallas Plastic Surgery Institute.

Received for publication September 3, 2018; accepted November 8, 2018.

Copyright © 2019 by the American Society of Plastic Surgeons

DOI: 10.1097/PRS.0000000000005521

bony egress from the iliac vein, a “nondirect hit” theory for pulmonary fat embolism caused by submuscular fat stretching and tearing of these veins has been raised.³ Although the conclusion from this prior study is that fat should be placed only in the subcutaneous space, some practitioners who perform gluteal fat grafting have questioned the potential for fat placed in the subcutaneous space to migrate into the deep submuscular space. Furthermore, some suggest that occasional unintended passes into the muscle can occur during fat grafting, which could cause perforations in the fascia, whereby fat could potentially enter and migrate into the deep submuscular space. The purpose of the present study was to define and to study subcutaneous migration, and to determine whether fat placed in the subcutaneous space under a variety of pressures and fascial integrity scenarios can indeed migrate into the deep submuscular space.

MATERIALS AND METHODS

Four hemibuttocks from two human cadavers (from the Dallas Plastic Surgery Institute) were used. Through a natal cleft incision, proxy fat (applesauce mixed with blue food coloring) was inserted using 60-cc syringes (scenarios 1 through 3) or using expansion vibration lipofilling (scenario 4). A Stryker manometer (Stryker, Inc., Kalamazoo, Mich.) was placed in the subcutaneous space to measure pressure at every 60 cc of grafting (Fig. 1).

Subcutaneous pressures were recorded after every 60 cc of injection. The reader, the recorder of the manometer, and the injector were separate individuals. The absence or presence of visual spreading of proxy fat in the subcutaneous tissues away from the location of the cannula tip was also assessed.

The hemibuttock scenarios differed as follows. In scenario 1, fat was inserted with a 60-cc syringe injection with fascia intact. In scenario 2, a random pattern of cannula perforations was made in the gluteus maximus fascia at its point of maximum projection before fat insertion. In scenario 3, 15 random defects in the gluteus maximus fascia were created with a 6-mm Baker punch biopsy knife after 2-cm skin incisions were made to allow for direct fascial visualization. These fenestrations were made along the points of maximum projection of the gluteus maximus muscle. Incisions were closed with a watertight running suture and reinforced with staples (Fig. 2). In scenario 4, proxy fat was inserted into the subcutaneous space

using expansion vibration lipofilling technique. This consisted of in-line placement of fat through a 4-mm exploded caged cannula and slanted canister (Black and Black, Atlanta, Ga.), silicone tubing, a roller pump, and a power-assisted reciprocating cannula device (Microaire, Inc., Charlottesville, Va.) (Fig. 3).

After the acquisition of these data, the skin and subcutaneous tissue of the posterior gluteal region were removed to examine the fascia of the gluteus maximus muscle and the submuscular space. After examination of the fascia, the gluteus maximus muscle was incised medially along its origin on the sacrum and reflected laterally toward the insertion on the greater trochanter to inspect the free submuscular space for the possible presence of fat.

RESULTS

Pressure-Volume Relationships

The pressure-volume data for each hemibuttock scenario are displayed in Table 1 and graphically in Figure 4.

Scenario 1: Syringe/Intact Fascia

In the intact fascia scenario, pressure increased in spikes and dips until it reached a pressure of approximately 125 to 150 mmHg and then plateaued. The pressure drops occurred following visible spreading of the proxy fat, presumably as pressure increased sufficiently to allow for movement of the proxy fat into adjacent spaces in the subcutaneous space by stretching and/or disruption of the superficial fascial system.

Disclosure: Dr. Wall a founder of SurgiStem Technologies, LLC, a medical device company involved in fat transplantation, and receives DVD royalties from Quality Medical Publishing. No funding was received for this article. Dr. Del Vecchio is a founder of SurgiStem Technologies, LLC, a device company involved in fat transplantation, receives royalties from Microaire, and is a founding member of Peninsula Partners, LLC, a consulting firm in the plastic surgery sector. Rod J. Rohrich, M.D., receives instrument royalties from Eriem Surgical, Inc., and book royalties from Thieme Medical Publishing; he is a Clinical and Research Study Expert for Allergan Inc., Galderma, and MTF Biologics, and the owner of Medical Seminars of Texas, LLC. No funding was received for this article. No disclosures for the remaining authors.

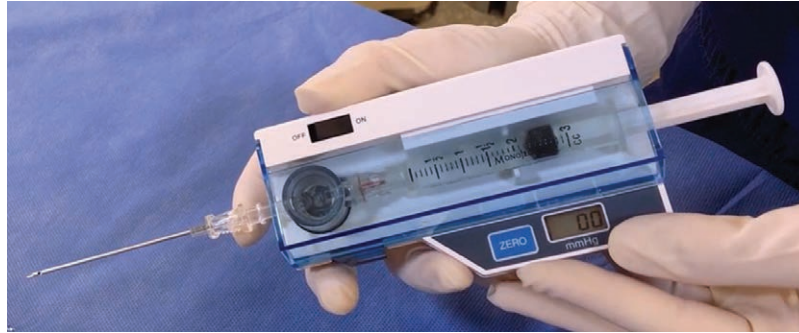

Fig. 1. Stryker manometer.

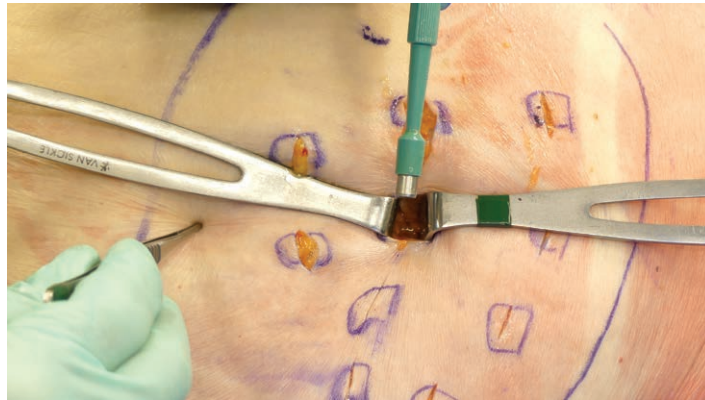

Fig. 2. In scenario 3, 15 random defects in the gluteus maximus fascia were created with a 6-mm Baker punch biopsy knife after 2-cm skin incisions were made to allow for direct fascial visualization. These fenestrations were made along the points of maximum projection of the gluteus maximus muscle. Incisions were closed with a watertight running suture and reinforced with staples.




Fig. 3. Expansion vibration lipofilling setup.

Downloaded from <http://journals.lww.com/plasreconsurg> by BhDM56PJKav1zEoun1tIQN4a+kLJNEZgbsIHd4XMI0hCywCX1AWnYqplllOrHD33D00dRy7TtVSFAcI3VC4/OAVpDDa8K2+Ya6H515KE= on 12/20/2024

Scenario 2: Syringe/Perforated Fascia

In scenario 2, the spiking and eventual plateau pattern of the pressure-volume curve was similar to scenario 1. The only difference was that the plateau pressure was higher than in scenario 1. This might be explained by the fact that this was a different cadaver with different subcutaneous capacities and different tissue tolerances.

Fifteen perforations were used in this model to simulate an exaggerated situation. Even with this many perforations and a pressure of 199 mmHg (the limit of the Stryker manometer), the fascia permitted only a small (1 cc) amount of proxy fat and dye to be noted beneath each perforation; no proxy fat spread deeper into the muscle or beneath it. On inspection, the edges of the fascia were noted to be in direct apposition to one another, not unlike a leaflet valve effect. In this scenario, despite suffering multiple perforations, fascial integrity remained robust and maintained a barrier function under extremely high pressures.

Scenario 3: Syringe/Fenestrated Fascia

In the fascia fenestrated scenario, pressure gradually rose to 50 mmHg at a volume of 550 cc, but fell to 25 mmHg, and gradually rose one more time to 50 mmHg, then fell again. There was not a spiking pattern and the pressures were strikingly

lower than with the intact fascia of scenario 1 and the perforated fascia of scenario 2. Although a visible protrusion of the skin increased as fat was injected in scenarios 1 and 2, in this scenario, buttock projection was not noticed to increase after the first several syringes were injected, with no visible subcutaneous migration observed in this scenario.

Scenario 4: Expansion Vibration Lipofilling/Intact Fascia

In the expansion vibration lipofilling scenario, pressure rose to a maximum of 30 mmHg at 600 cc and went through several additional sinusoidal cycles, approaching terminal volumes. The pressure-volume relationships were less jagged than those seen in scenarios 1 and 2. The pressures remained significantly lower than the intact fascia scenario of scenario 1 and the perforated fascia of scenario 2. In addition, the expansion vibration lipofilling scenario exhibited minimal to no visible subcutaneous migration. This scenario never caused a significant rise in subcutaneous pressure, even after placement of 1500 cc.

Postinfiltration Dissection

After the infiltrations were completed, a curvilinear C-shaped incision was made from the superolateral buttocks to the natal cleft, and then curved inferolaterally along the inferior gluteal crease. The muscle was then reflected laterally along its insertion onto the greater trochanter, exposing the submuscular (subgluteal) space, in which the superior and inferior gluteal veins and sciatic nerve were visible. The gluteus maximus fascia was also evaluated by dissecting the subcutaneous tissues off of the fascia in the same pattern as the submuscular dissection.

In buttocks 1 and 4 (syringe/intact fascia and expansion vibration lipofilling/intact fascia), no applesauce or discoloration was noted beneath the muscle. The integrity of the gluteus maximus fascia was noted to be intact in both scenarios, without any evidence of proxy fat or discoloration deep to the fascia, demonstrating a lack of deep intramuscular migration.

Similarly, in scenario 2 (syringe/perforated fascia), no applesauce or discoloration was noted beneath the muscle, and as expected, the integrity of the gluteus maximus fascia was noted to be compromised with multiple perforations. A small amount (1 cc) of proxy fat and dye was observed in the superficial muscle just beneath the perforations but without any evidence of deep intramuscular migration. In scenario 3 (fenestrated

Table 1. Pressure-Volume Data for Each Hemibuttock Scenario

Volume (cc)	Intact (mmHg)	Perforated (mmHg)	Fenestrated (mmHg)	EVL (mmHg)
0	0	2	1	0
60	63	11	3	2
120	50	23	5	3
180	113	19	8	8
240	134	34	18	13
300	66	47	27	10
360	150	130	28	13
420	150	94	46	12
480	98	199	43	25
540	115	199	55	22
600	117	132	38	24
660	117	152	24	30
720	116	150	28	15
780	122	170	25	8
840	123	199	28	20
900	127	199	34	25
960	127	136	40	26
1020	124	199	43	26
1080	120	174	48	30
1140	117	187	52	11
1200	116	172	56	21
1260	115	199	57	11
1320	116	199	46	18
1380	119	172	45	23
1440	120	193	42	25
1500	122	177	45	15

EVL, expansion vibration lipofilling.

Downloaded from http://journals.lww.com/plasreconsurg by BhdMf56PHkav1zEounm1iQIN4+kULHEZgbslHo4XMIIO on 12/20/2024

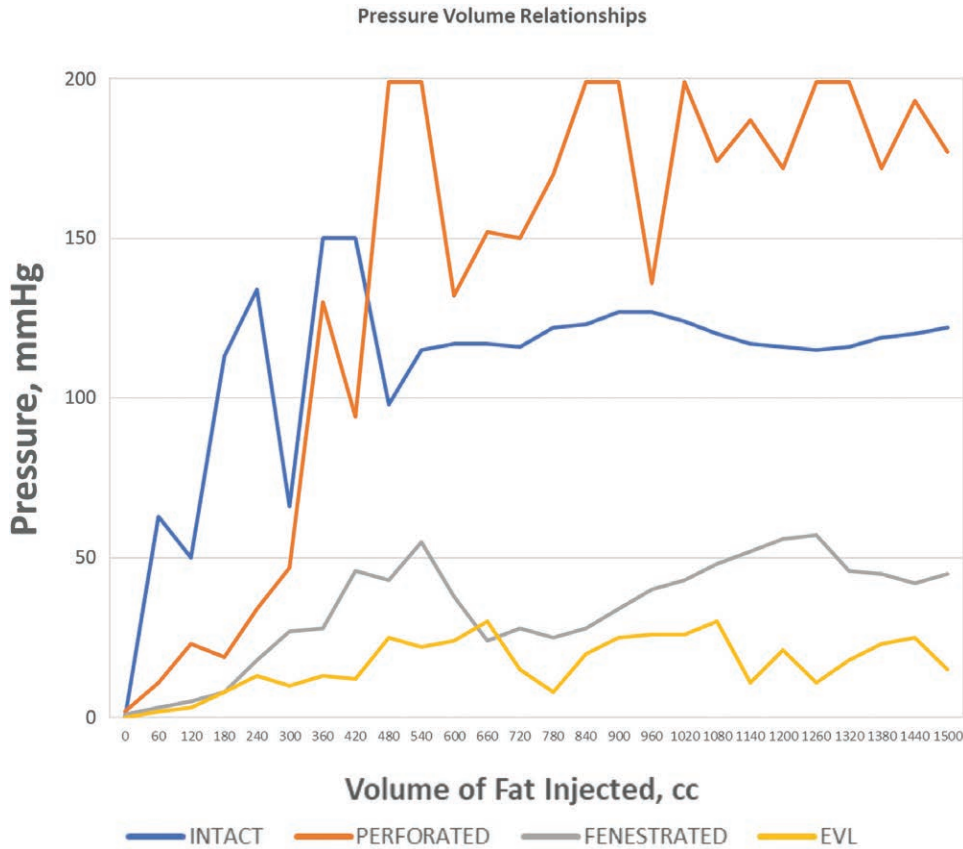


Fig. 4. Pressure-volume relationship graph. EVL, expansion volume lipofilling.

fascia), the submuscular space contained a significant amount of proxy fat. Applesauce and dye were noted within the muscle, but the largest quantity of fat could be seen to emanate from underneath the most inferolateral portion of the muscle which, in the prone position, is the most dependent space (Fig. 5). The 6-mm fascial fenestrations in scenario 3 allowed the proxy fat to flow freely beneath the muscle in exactly the same pattern as did subfascial injections in the deep intramuscular migration article. The dramatically different pressure-volume curve of scenario 3 can only be explained by the fenestrations. That fat more readily migrated through muscle than in the subcutaneous layer gives further indirect evidence of the propensity for deep intramuscular migration with any subfascial injection. (See Video, Supplemental Digital Content 1, which demonstrates subcutaneous migration in an anatomical study of gluteal fat grafting, available in the “Related Videos” section of the full-text article on PRSJJournal.com or, for Ovid users, available at <http://links.lww.com/PRS/D405>.)

DISCUSSION

Subcutaneous Migration Defined

The concept of subcutaneous migration had its origins in the observation that during expansion vibration lipofilling, transplanted fat was observed to travel very rapidly through tissues, beyond the point of cannula insertion.⁴ In addition, our prior experience with deep intramuscular migration suggested that we consider the same phenomenon might be occurring in the subcutaneous plane. When recipient-site pressure immediately adjacent to the cannula tip exceeds ambient recipient-site pressure, a gradient is created and the potential for fat flow is initiated. The resistance to this flow is predicated on the integrity of the connective tissue matrix. We define this movement of fat in the subcutaneous space as subcutaneous migration. During subcutaneous migration, fat flows to the path of least resistance. This may not necessarily be the desired location of grafted fat, with uncontrolled subcutaneous migration resulting in aesthetic disharmony at least, and at worst, lakes of fat from excessive connective tissue disruption or fractures referred to as

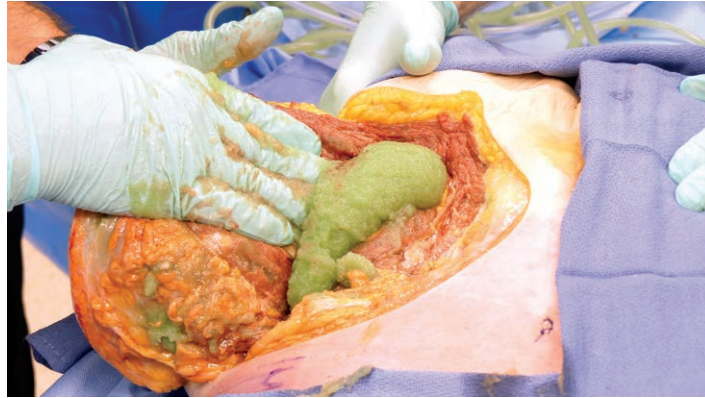


Fig. 5. Fenestrated fascia scenario. The applesauce and dye were noted within the muscle, but the largest quantity of fat could be seen to emanate from underneath the most inferolateral portion of the muscle.

“blowouts.” Expansion vibration lipofilling seeks to control the direction and extent of subcutaneous migration, by preferentially disrupting connective tissue to achieve targeted fat placement. In this sense, expansion vibration lipofilling is a subset of subcutaneous migration.

Fascial Perforation and Bolus Analysis

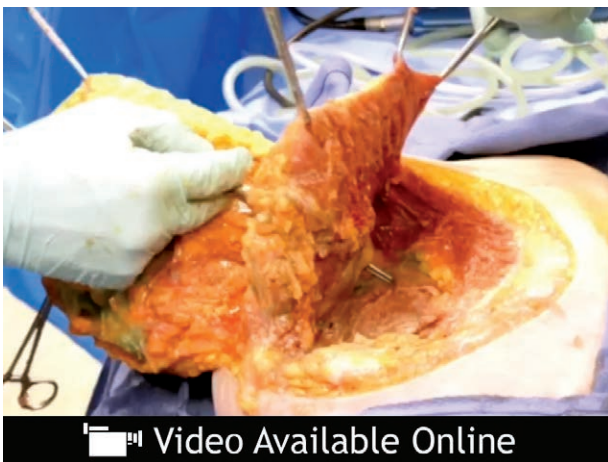Although our experimental protocol sought to simulate fascial integrity scenarios in clinical fat grafting, there were some limitations that deserve discussion. In scenario 2, the fascial perforations were made, followed by fat grafting, but not simultaneously with fat grafting. This may have underrepresented the amount of fat that could get beneath the fascia, given an inadvertent pass. During intended

“subcutaneous only” Brazilian buttock lift, inadvertent passes beneath the gluteus maximus fascia most certainly occur. However, the volumes of fat placed during these passes are not likely to be of significant enough volume to cause deep intramuscular migration into the submuscular space.

There are two currently used clinical methods to transplant fat to the buttocks in large volume: classic syringe injection and expansion vibration lipofilling. Assuming a range of syringes of 10, 30, and 60 cc, which are routinely used, with volumes of fat placed with each cannula pass ranging from 15 to 45 percent of the syringe volume, the following bolus data are generated (Table 2).

For expansion vibration lipofilling, assuming infusion pump flow rates between 300 cc/minute and a maximum of 500 cc/minute (most pumps have a maximum flow rate of 300 cc/minute), and assuming the period the cannula remains beneath the fascia is between 1 and 3 seconds, the following bolus data for expansion vibration lipofilling are generated (Table 3).

Even at the most aggressive ends of these models, it is unlikely that a 25- to 27-cc bolus of fat within the gluteus maximus muscle would be significant enough to cause vascular or sciatic nerve injury in the deep muscular space, by means of deep intramuscular migration. This “inadvertent pass” scenario is probably the most important scenario to consider in making the distinction between subcutaneous-only Brazilian buttock lift and Brazilian buttock lift strategies that aim to place fat in the muscle. Although inadvertent passes may only result in at maximum 25 cc of fat, intramuscular fat grafting strategies are substantially higher, as no surgeon plans an intramuscular fat transplantation strategy with only 25 cc of fat in mind.



Video. Supplemental Digital Content 1 demonstrates subcutaneous migration in an anatomical study of gluteal fat grafting, available in the “Related Videos” section of the full-text article on PRSJournal.com or, for Ovid users, available at <http://links.lww.com/PRS/D405>.

Table 2. Syringe Injection Bolus Data

Syringe Volume (cc)	Percentage of Syringe per Pass		
	15% (cc)	30% (cc)	45% (cc)
10	1.5	3	4.5
30	4.5	9	13.5
50	9	18	27

Table 3. Expansion Vibration Lipofilling Flow Data

Time Beneath Fascia (sec)	EVL Flow Rate		
	300 (cc)	400 (cc)	500 (cc)
1	5.0	6.7	8.3
2	10	13.3	16.7
3	15.0	20.0	25.0

Gluteal Fat Transplantation and the Patient Safety Landscape

Gluteal fat grafting has historically been a relatively unpopular procedure in the United States, with little awareness of serious side effects until 2015 when Cárdenas-Camarena et al. published a series of 22 deaths in Colombia and Mexico.² One year later, the Aesthetic Surgery Education and Research Foundation Gluteal Fat Grafting Task Force, based on a retrospective survey study of American Society for Aesthetic Plastic Surgery members, estimated a one in 3000 mortality rate with the procedure.⁵ Autopsy findings have uniformly shown intramuscular and submuscular fat around and in the gluteal vessels; there has never been a death with fat found only in the subcutaneous tissue.

We recently demonstrated in a dynamic cadaver study that with sufficient pressure, injections of proxy fat (dyed applesauce) placed immediately beneath the gluteus maximus fascia can migrate deeply through the muscle into the submuscular space, which contains the superior and inferior gluteal veins and the sciatic nerve.³ We termed this deep intramuscular migration. Del Vecchio first proposed that as traction on the gluteal veins increases from fat expanding the submuscular space, the stretching of this rich and cavernous venous plexus may result in tears that allow migrated fat to be siphoned into the low-pressure venous system, the so-called venous traction phenomenon.⁶ Our prior dynamic anatomical study showed that in even the most superficial subfascial injection, in any region of the gluteus maximus, large volumes of fat can result in deep intramuscular migration and are potentially unsafe. In addition to the venous traction phenomenon, direct injury to the veins (i.e., a laceration with the cannula in the intramuscular space)

is also possible, and the fat is then subsequently siphoned into the low-pressure venous system. In contrast, with subcutaneous-only injections, the proxy fat did not cross deep to the fascia, staying entirely in the subcutaneous space. These findings gave strong anatomical support to the belief that subcutaneous injection is safer than intramuscular injection, leading to our recommendation that gluteal fat be grafted only into the subcutaneous space. These findings served as the basis for the urgent safety advisory sent by a multisociety task force to plastic surgeons worldwide on July 13, 2018, declaring that subcutaneous-only injections be standard.⁷⁻¹²

Limitations of Subcutaneous-Only Gluteal Grafting

Some surgeons have voiced concern that subcutaneous-only injections will limit the amount of fat that can be grafted and remain viable. Even if true, it is not a justification to risk intramuscular injection. As with tenets learned from multistage aesthetic procedures such as hair transplantation and some applications of fat transplantation to the breast, if a single procedure to the buttocks cannot attain the desired result, the procedure should be staged, expectations should be managed, implants should be considered, or some combination thereof should be performed.¹³

Another concern with subcutaneous-only fat transplantation is that it is not possible to stay in the subcutaneous plane. A recent publication described using real-time ultrasound to follow the cannula and confirm that the cannula stayed in the subcutaneous plane.¹⁴ In the best of hands, this added nearly 30 minutes to the average operative time of grafting an average of only 528 cc of fat per side. The authors noted other significant downsides, such as cost, a learning curve, and the need to have an assistant surgeon present to follow along with the cannula movement. Considering the inadvertent pass subfascial bolus analysis above, this places into question the need for artificial intelligence modalities that keep the surgeon in the subcutaneous plane.

It should be technically possible to consistently stay in the subcutaneous plane with gluteal fat grafting as it is with liposuction.¹⁵ During gluteal fat grafting, a cannula is used to insert fat into a recipient site. During liposuction, a cannula is also placed in the subcutaneous space to extract fat from a donor site. Comparatively, both gluteal fat grafting and liposuction of the abdomen have a subcutaneous target zone with an underlying “soft” fascial barrier and without a “hard

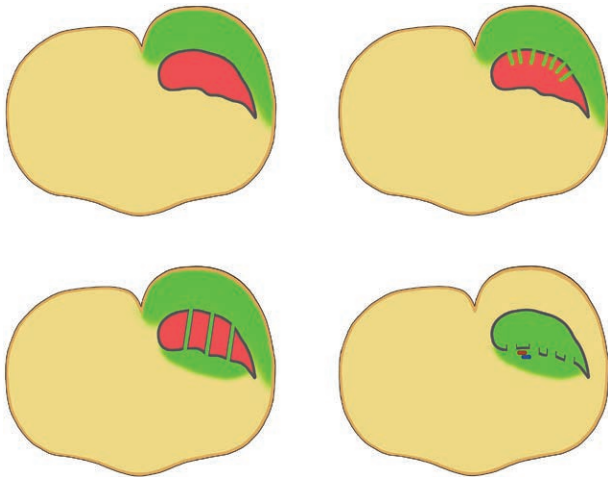


Fig. 6. Summary of findings. (Above, left) Fascia intact. Subcutaneous migration occurs. (Above, right) Fascial perforations. Subcutaneous migration occurs but no deep intramuscular migration occurs. (Below, left) Fascial fenestrations. Deep intramuscular migration occurs. (Below, right) Subfascial injection leads to deep intramuscular migration of fat.

stop” beneath the fascia. Although there is clear evidence for cannula misadventure during liposuction with injury to abdominal organs,^{16–18} this complication is exceedingly rare, as should be the injury rate to the gluteal vessels in gluteal augmentation. We believe the key is patient positioning, incision location, and a highly focused attention to the location of the cannula with every pass during grafting, allowing the surgeon to avoid subfascial fat grafting.

There are ongoing studies evaluating “danger zones,” “safe zones,” and angles of cannula insertion that might be least likely to cause direct venous or sciatic nerve injury.^{2,5,19–22} Although these research efforts are to be commended, they do not take into account our findings that any injection deep to the fascia *in any part of the buttock* can lead to deep intramuscular migration, a venous stretch-tear-siphon phenomenon, and ultimately, a fatal fat embolism. Some surgeons still feel that intramuscular injection is necessary for adequate augmentation, and giving these surgeons a false sense of security that there are “safe zones” of the buttock and “safe” cannula angles so they could inject somewhat deeper may have the unintended consequences of propagating the problem. At worst, guidelines that focus on how to avoid directly injuring the gluteal veins with a cannula can convey to some surgeons that there are safe ways to perform intramuscular injections.

Recommendations

Given our findings, we recommend that any subfascial or deeper gluteal fat grafting should not be performed whatsoever, and that subcutaneous injections appear to avoid any direct or indirect injury to the gluteal veins and should be used exclusively for this operation. Surgeons who are unsuccessful performing subcutaneous-only injections should consider using gluteal implants or performing a composite implant/fat augmentation.

CONCLUSIONS

In our deep intramuscular migration study (Part I), it was shown that subfascial injection of proxy fat could migrate by means of the process of deep intramuscular migration through and out the deep surface of the gluteus maximus muscle, putting the gluteal veins at risk to be an entry point for a gluteal fat embolism.^{3,23} In this study, it was shown that the gluteus maximus fascia, even with multiple cannula perforations, prevented subcutaneous injections to cross into the muscle, even under very high injection pressures (Fig. 6). Instead, the fat would migrate throughout the subcutaneous tissue by means of a process called subcutaneous migration. The gluteus maximus fascia is a stout wall that sets up the dangerous condition of deep intramuscular migration with subfascial injections, and the protective condition of subcutaneous migration with suprafascial injections. These persuasive findings are profound enough to propose a new standard of care: no subfascial or intramuscular injection should be performed, and all injections should be performed exclusively into the subcutaneous tissue. Today, surgeons should commit to subcutaneous-only injection and maintain constant focus during surgery. Research efforts should concentrate on methods to maintain a subcutaneous injection plane.

Simeon Wall, Jr., M.D.

The Wall Center for Plastic Surgery
8600 Fern Avenue
Shreveport, La. 71105
swalljr@wallcenter.com

ACKNOWLEDGMENT

The authors thank Brian Brown of Stryker for the compartment pressure monitor.

REFERENCES

1. American Society for Aesthetic Plastic Surgery. Cosmetic surgery national data bank statistics 2017. Available at: <https://www.surgery.org/media/statistics>. Accessed August 1, 2018.
2. Cárdenas-Camarena L, Bayter JE, Aguirre-Serrano H, Cuenca-Pardo J. Deaths caused by gluteal lipoinjection: What are we doing wrong? *Plast Reconstr Surg*. 2015;136:58–66.
3. Delvecchio D, Villanueva NL, Mohan R, et al. Clinical implications of gluteal fat graft migration: A dynamic anatomical study. *Plastic Reconstr Surg*. 2018;142:1180–1192.
4. Wall S Jr. Expansion vibration lipofilling: A new technique in large-volume fat transplantation: Correction. *Plast Reconstr Surg*. 2018;142:295.
5. Mofid MM, Teitelbaum S, Suissa D, et al. Report on mortality from gluteal fat grafting: Recommendations from the ASERF task force. *Aesthet Surg J*. 2017;37:796–806.
6. Del Vecchio D. Safety of gluteal fat transplantation: A lecture video by Daniel Del Vecchio, MD from the 52nd Annual Baker Gordon Symposium on Cosmetic Surgery. *Plast Reconstr Surg*. 2018;142.
7. American Society of Plastic Surgeons. Newly-formed task force provides guidance to surgeons in wake of multiple deaths resulting from popular procedure. Available at: <https://www.plasticsurgery.org/news/press-releases/plastic-surgery-societies-issue-urgent-warning-about-the-risks-associated-with-brazilian-butt-lifts>. Accessed August 15, 2018.
8. Business Wire. Dr. Grant Stevens addresses Brazilian butt lift complications: Inter-society gluteal fat grafting task force conducting extensive research to prevent tragic outcomes. Available at: <https://www.businesswire.com/news/home/20180803005118/en/Dr.-Grant-Stevens-Addresses-Brazilian-Butt-Lift>. Accessed August 15, 2018.
9. GMA Team; ABC News. Plastic surgeons' group issues new warning over Brazilian butt lift procedure. Available at: <https://abcnews.go.com/GMA/Wellness/plastic-surgeons-group-issues-warning-brazilian-butt-lift/story?id=56980264>. Accessed August 15, 2018.
10. NBC News. Dying for a bigger butt: Doctors take action after deaths. Available at: https://www.nbcmiami.com/on-air/as-seen-on/Dying-For-a-Bigger-Butt_Doctors-Take-Action-After-Deaths_Miami-489591201.html. Accessed August 15, 2018.
11. American Society for Aesthetic Plastic Surgery. Five of the world's preeminent plastic and cosmetic surgery-related organizations band together to research complications and deaths associated with the Brazilian buttock lift: Inter-society gluteal fat grafting task force conducting extensive research to prevent tragic outcomes. Available at: <https://www.surgery.org/media/news-releases/five-of-the-worlds-preeminent-plastic-and-cosmetic-surgery-related-organizations-band-together-to-research-c>. Accessed August 15, 2018.
12. Rahhal N; Daily Mail. Women are dying for bigger butts: 33 patients have died on US surgical tables in just 5 years, top plastic surgeons reveal - as they call to change how Brazilian butt lifts are performed. Available at: <https://www.dailymail.co.uk/health/article-6023579/Worlds-plastic-surgeons-warn-Brazilian-butt-lifts-deadly-cosmetic-procedure.html>. Accessed August 15, 2018.
13. Delay E, Guerid S. The role of fat grafting in breast reconstruction. *Clin Plast Surg*. 2015;42:315–323, vii.
14. Cansanco AL, Condé-Green A, Vidigal RA, Rodriguez RL, D'Amico RA. Real-time ultrasound-assisted gluteal fat grafting. *Plast Reconstr Surg*. 2018;142:372–376.
15. Wall SH Jr, Lee MR. Separation, aspiration, and fat equalization: SAFE liposuction concepts for comprehensive body contouring. *Plast Reconstr Surg*. 2016;138:1192–1201.
16. King SH, Miller J, Kuan JK. Intraperitoneal bladder rupture after abdominal liposuction. *Plast Reconstr Surg*. 2008;122:228e–229e.
17. Matarasso A, Swift RW, Rankin M. Abdominoplasty and abdominal contour surgery: A national plastic surgery survey. *Plast Reconstr Surg*. 2006;117:1797–1808.
18. Talmor M, Fahey TJ II, Wise J, Hoffman LA, Barie PS. Large-volume liposuction complicated by retroperitoneal hemorrhage: Management principles and implications for the quality improvement process. *Plast Reconstr Surg*. 2000;105:2244–2248; discussion 2249–2250.
19. Villanueva NL, Del Vecchio DA, Afrooz PN, Carboy JA, Rohrich RJ. Staying safe during gluteal fat transplantation. *Plast Reconstr Surg*. 2018;141:79–86.
20. Ramos-Gallardo G, Orozco-Renteria D, Medina-Zomora P, et al. Prevention of fat embolism in fat injection for gluteal augmentation: Anatomic study in fresh cadavers. *J Invest Surg*. 2017;31:292–297.
21. Rosique RG, Rosique MJ. Deaths caused by gluteal lipoinjection: What are we doing wrong? *Plast Reconstr Surg*. 2016;137:641e–642e.
22. Cardenas-Mejia A, Martínez JR, León D, Taylor JA, Gutierrez-Gomez C. Bilateral sciatic nerve axonotmesis after gluteal lipoaugmentation. *Ann Plast Surg*. 2009;63:366–368.
23. Delvecchio D, Villanueva NL, Mohan R, et al. Defining the migration of fat in gluteal augmentation: A dynamic anatomic study. Paper presented at: 52nd Annual Baker Gordon Symposium; February 8–10, 2018; Miami, Fla.