

Unique Uses of SPY: High-risk Facelift

Mikaela L. Kislevitz, BSN, RN
 Karen B. Lu, MD
 Kyle Sanniec, MD, MHA
 Bardia Amirlak, MD, FACS

Summary: Skin flap necrosis occurs in 1–3% of facelift procedures. The SPY Elite Fluorescence Imaging System has been widely used in evaluating mastectomy skin flaps for breast reconstruction but has not been described in assessing skin flaps during facelifts. This case report describes the intraoperative use of SPY to assess flap perfusion during a high-risk facelift and static sling for the correction of facial paralysis. The use of intraoperative SPY during this high-risk facelift allowed for the timely assessment of perfusion, successful intervention of nitroglycerin paste to improve blood flow, and prevention of any additional surgical interventions. SPY may have a more widespread role in facelift patients with a higher risk of skin flap necrosis. (*Plast Reconstr Surg Glob Open* 2019;7:e2183; doi: 10.1097/GOX.0000000000002183; Published online 25 June 2019.)

Facelift surgery has evolved from “skin-only” techniques to performing superficial musculoaponeurotic system dissection.¹ Even with technique changes, facelift complications including hematomas, nerve injury, and skin necrosis remain.¹ Surgeons can evaluate tissue perfusion clinically by assessing bleeding during flap dissection and measuring flap thickness and prevent ischemia by limiting subcutaneous dissection to preserve blood supply. Elevating the skin flap can result in hypoperfusion to the distal aspect of the flap, and this vascular supply can be further diminished in the setting of previous radiation or nicotine use.² Skin flap necrosis rates can be decreased with the ability to assess perfusion using the SPY Elite laser angiographic system (Stryker Corp/Novadaq Technologies, Kalamazoo, Mich.).³

The SPY technology visualizes perfusion by following the diffusion of indocyanine green dye through the vasculature, providing real-time data on tissue perfusion.⁴ Direct visualization with SPY provides objective clinical information on the perfusion of skin flaps and allows for the evaluation of intraoperative interventions such as nitroglycerin paste. Nitroglycerin paste, an intervention for increasing vascular perfusion, can prevent mastectomy skin flap necrosis through dilation of blood vessels.^{5–7}

Although SPY has been successfully utilized in evaluating mastectomy skin flaps, sentinel lymph nodes in melanoma, and during abdominal and lower extremity reconstruction,^{8–11} it has not been described in the management of a facelift procedure. This case report demon-

strates the innovative application of SPY angiography in high-risk facelift patients.

CLINICAL REPORT

A 75-year-old male with a history of right parotid tumor, treated with chemoradiation and resection resulting in right facial nerve palsy, presented for a facelift consultation. He had significant right-sided facial atrophy with loss of volume and laxity of the tissue (Fig. 1). Facial nerve reanimation was offered to the patient; however, the patient desired resuspension of the soft tissue of the right midface instead.

The patient underwent right unilateral rhytidectomy and static sling procedure using fascia lata. A standard retroragal curvilinear pretrichial facelift incision was made, and thicker skin flaps were elevated during the dissection. A limited superficial musculoaponeurotic system flap was raised and plicated with suspension sutures from the deep temporal fascia. The skin dissection was carried down to the modiolus, where the harvested fascia lata was used as a suspension sling, which decreased the tension on the skin flaps.

The skin was redraped with the minimal trimming of excessive skin to prevent any tension on the incision. The patient’s history of radiation and scarring made it difficult to fully assess perfusion of the skin flap. During final skin closure, 3–4 cm of the edges of the skin flap demonstrated discoloration concerning for ischemia (Fig. 2). Given the concern for tissue perfusion and an unreliable clinical examination, thought was given to removing the suspension sutures to further decrease tension on the flap, which would be tantamount to aborting the procedure.

An intraoperative SPY was performed to assess perfusion of the lateral face. Dye was injected approximately 3 hours after incision. SPY imaging showed dark areas on the lateral

From the University of Texas Southwestern Medical Center, Dallas, Tex.

Received for publication November 19, 2018; accepted January 15, 2019.

Copyright © 2019 The Authors. Published by Wolters Kluwer Health, Inc. on behalf of The American Society of Plastic Surgeons. This is an open-access article distributed under the terms of the Creative Commons Attribution-Non Commercial-No Derivatives License 4.0 (CCBY-NC-ND), where it is permissible to download and share the work provided it is properly cited. The work cannot be changed in any way or used commercially without permission from the journal.

DOI: 10.1097/GOX.0000000000002183

Disclosure: The authors have no financial interest to declare in relation to the content of this article. The Article Processing Charge was paid for by an educational grant from Stryker Corp/Novadaq Technologies Inc. for SPY Elite laser angiographic system.

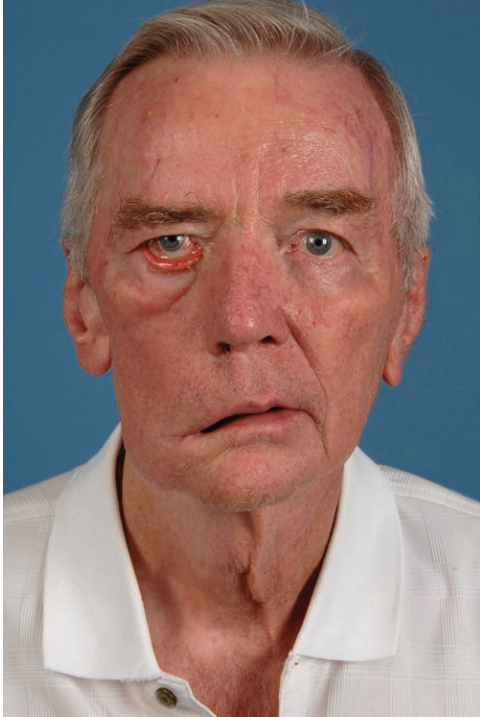

Fig. 1. Preoperative image of patient. This image depicts the patient preoperatively. He has significant right-sided facial atrophy with loss of volume and laxity of the tissue. In addition, he has right-sided scleral show with ectropion.

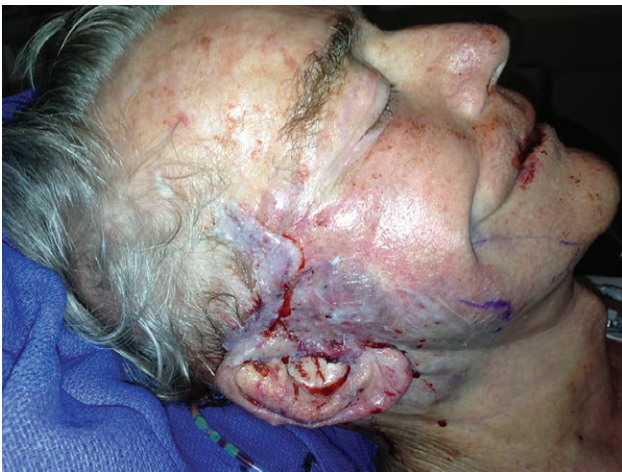

Fig. 2. Intraoperative image of patient. This image depicts the dusky skin during procedure.

aspect of the skin flap (Fig. 3), which was concerning for progression to full ischemia. Although epinephrine can result in decreased perfusion, this was unlikely given that a 40cm³ of a 50:50 mixture of 1% lidocaine and 0.5% ropivacaine with 1:200,000 of epinephrine was injected several hours before SPY angiography at the beginning of the case. In addition, other distal areas where epinephrine was injected were shown to have adequate perfusion. Nitroglycerin paste was applied and imaging postintervention (5 minutes) showed increased perfusion within the threshold for tissue

viability (Fig. 4). The paste was continued on an outpatient basis allowing the skin to fully heal with no evidence of skin flap compromise. The patient reported an improvement in his facial symmetry, drooping, and jaw angulation. He continued to follow-up and elected to have a facelift on his left side to further improve his facial symmetry.

DISCUSSION

This patient had a history of radiation and scarring from tumor resection, which can compromise the vascularity of the treated area during skin flap elevation. Intraoperative SPY was utilized as a diagnostic tool to localize areas of poor perfusion. This identification allowed for immediate treatment. Without the use of SPY to confirm increased perfusion after treatment with nitroglycerine paste, all of the sutures would have been released to decrease tension on the flap and the patient would have needed another operation. However, the SPY imaging showed adequate perfusion after nitroglycerin paste application and allowed for a safe completion of the procedure. In this case, the use of SPY intraoperatively prevented prolonged operative time, complications, and reoperation.

The use of SPY angiography was invaluable intraoperatively in assessing perfusion in the high-risk facelift patient. In this case, poor perfusion was visualized using the SPY and the efficacy of nitroglycerin paste in treating the hypoperfused areas was confirmed.

As the utilization cost of the SPY system continues to decline, its use in cosmetic procedures or reconstructive rhytidectomies may be more justified. Clinical judgment and other methods of perfusion analysis such as Wood's lamp examination with fluorescein can be less reliable than SPY, and the efficacy of intraoperative treatment for hypoperfusion is often not able to be evaluated in real time. In this case, confirmation of increased perfusion was seen with SPY following application of nitroglycerin, preventing additional intervention, and confirming the effectiveness of the treatment. The patient experienced no complications and noticed improvement in his facial symmetry and oral function. Although not recommended in every facelift, in high-risk patients, where tissue vascularity is questionable, the use of SPY to assess tissue perfusion and evaluate the efficacy of intraoperative interventions is a valuable tool of the plastic surgeon to have in their armamentarium.

SUMMARY

This case demonstrates the successful utilization of the SPY in a high-risk facelift procedure. SPY imaging altered the surgeons' decision in favor of a less aggressive intervention, without inpatient monitoring and additional treatments. With appropriate patient selection, SPY may be integrated as an essential component of plastic surgery procedures involving skin flaps and possible ischemia.

Bardia Amirlak, MD, FACS

Department of Plastic Surgery
University of Texas Southwestern Medical Center
1801 Inwood Road
Dallas, TX 9132

E-mail: bardia.amirlak@utsouthwestern.edu

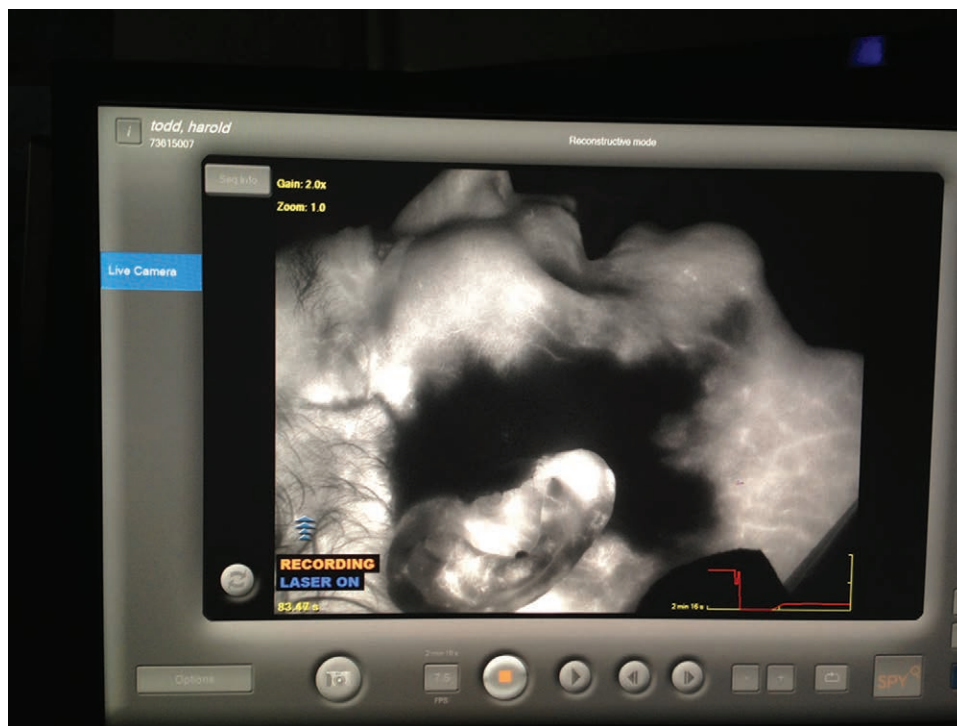

Fig. 3. SPY angiography imaging before intervention of nitroglycerine paste. SPY imaging shows dark areas on the lateral aspect of the skin flap.

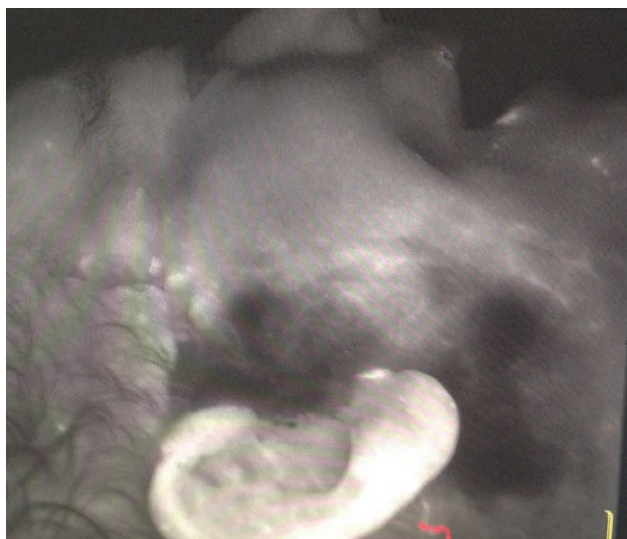


Fig. 4. SPY angiography imaging after intervention of nitroglycerine paste. SPY imaging shows increased perfusion on the lateral aspect of the skin flap.

REFERENCES

1. Bloom JD, Immerman SB, Rosenberg DB. Face-lift complications. *Facial Plast Surg.* 2012;28:260–272.
2. Abedi N, Ho AL, Knox A, et al. Predictors of mastectomy flap necrosis in patients undergoing immediate breast reconstruction: a review of 718 patients. *Ann Plast Surg.* 2016;76:629–634.
3. Duggal CS, Madni T, Losken A. An outcome analysis of intraoperative angiography for postmastectomy breast reconstruction. *Aesthet Surg J.* 2014;34:61–65.
4. Munabi NC, Olorunnipa OB, Goltsman D, et al. The ability of intra-operative perfusion mapping with laser-assisted indocyanine green angiography to predict mastectomy flap necrosis in breast reconstruction: a prospective trial. *J Plast Reconstr Aesthet Surg.* 2014;67:449–455.
5. Sannic K, Teotia S, Amirlak B. Management of tissue ischemia in mastectomy skin flaps: algorithm integrating SPY angiography and topical nitroglycerin. *Plast Reconstr Surg Glob Open.* 2016;4:e1075.
6. Turin SY, Li DD, Vaca EE, et al. Nitroglycerin ointment for reducing the rate of mastectomy flap necrosis in immediate implant-based breast reconstruction. *Plast Reconstr Surg.* 2018;142:264e–270e.
7. Gdalevitch P, Van Laeken N, Bahng S, et al. Effects of nitroglycerin ointment on mastectomy flap necrosis in immediate breast reconstruction: a randomized controlled trial. *Plast Reconstr Surg.* 2015;135:1530–1539.
8. Colvard B, Itoga NK, Hitchner E, et al. SPY technology as an adjunctive measure for lower extremity perfusion. *J Vasc Surg.* 2016;64:195–201.
9. Wormer BA, Huntington CR, Ross SW, et al. A prospective randomized double-blinded controlled trial evaluating indocyanine green fluorescence angiography on reducing wound complications in complex abdominal wall reconstruction. *J Surg Res.* 2016;202:461–472.
10. Gorai K, Inoue K, Saegusa N, et al. Prediction of skin necrosis after mastectomy for breast cancer using indocyanine green angiography imaging. *Plast Reconstr Surg Glob Open.* 2017;5:e1321.
11. Cloyd JM, Wapnir IL, Read BM, et al. Indocyanine green and fluorescence lymphangiography for sentinel lymph node identification in cutaneous melanoma. *J Surg Oncol.* 2014;110:888–892.