

Management of Tissue Ischemia in Mastectomy Skin Flaps: Algorithm Integrating SPY Angiography and Topical Nitroglycerin

Kyle Sanniec, MD
Sumeet Teotia, MD
Bardia Amirlak, MD, FACS

Summary: Tissue ischemia can be managed in several different ways based on the cause of the perfusion defect, including topical nitroglycerin or surgical intervention. However, there are times when tissue perfusion is questioned and clinical examination is unable to determine definitively the cause of ischemic tissue and whether it will survive. In this technique article, we describe our comprehensive algorithm for the management of tissue ischemia in mastectomy skin flaps, which can be applied to other plastic surgery procedures by integrating SPY angiography and topical nitroglycerin. (*Plast Reconstr Surg Glob Open* 2016;4:e1075; doi: 10.1097/GOX.0000000000001075; Published online 6 October 2016.)

Tissue perfusion frequently guides plastic surgeons' operative decision making. Surgeons have relied primarily on clinical exam to assess tissue perfusion, which can be unpredictable in challenging situations such as echymotic skin, patients of darker skin tones, and tissues without a cutaneous component. The advent of SPY angiography has made real-time evaluation of tissue perfusion possible, which has provided objectivity to surgical decision-making and correlated positively with clinical outcomes.¹⁻⁴

Scenarios in which tissue perfusion is questioned, but the tissue of interest is esthetically or functionally indispensable, often require the surgeon to perform different surgical techniques to salvage the tissue but ultimately may lead to total abandonment of the reconstruction. Utilizing pharmacologic agents to salvage tissues has gained some attention in recent years.⁵ Combining this with real-time imaging of the cutaneous microvasculature with indocyanine green (ICG) and SPY angiography allows objective and targeted assessment of tissue perfusion and provides predictability in these scenarios.

The SPY Elite laser angiographic system (Novadaq Technologies, Concord, ON, Canada) is based on the chemical properties of ICG. ICG is safe and has a rapid

half-life of 150 to 180 seconds. It binds to plasma proteins, is on the infrared spectrum, and remains in circulation, making it useful for identifying vascularity.⁶⁻¹⁰

The images are displayed on screen in real time to allow for intraoperative decision-making. The SPY-Q analysis software allows for quantification of perfusion by assigning numeric values based on the intensity of the fluorescence compared with a reference value based on the intensity of tissue outside the area of interest.⁷ Additionally, the short half-life of ICG allows for multiple evaluations of tissue perfusion, especially after a surgical intervention (cutting skin flaps, undermining soft tissue, use of rapid pharmacologic vasodilators, etc.).

The use of SPY angiography has also been shown to decrease costs. A recent cost analysis of SPY angiography in prevention of mastectomy skin flap necrosis demonstrated cost savings of anywhere between \$1900.00 and \$2100.00 in high-risk groups¹¹ and improved mastectomy flap survival.^{12,13}

One of the interventions that can be done for tissue ischemia is the use of topical nitroglycerin paste. Nitroglycerin causes arterial and venous dilation and has been used to increase perfusion to ischemic tissues. It has been shown to prevent mastectomy skin flap necrosis.¹⁴⁻¹⁶ However, like all pharmacologic interventions, there are adverse effects that must be weighed before starting topical nitroglycerin. These adverse effects can range from headache and

From the Department of Plastic Surgery, University of Texas Southwestern Medical Center, Dallas, Tex.

Received for publication March 28, 2016; accepted August 15, 2016.

Copyright © 2016 The Authors. Published by Wolters Kluwer Health, Inc. on behalf of The American Society of Plastic Surgeons. All rights reserved. This is an open-access article distributed under the terms of the Creative Commons Attribution-Non Commercial-No Derivatives License 4.0 (CCBY-NC-ND), where it is permissible to download and share the work provided it is properly cited. The work cannot be changed in any way or used commercially.

DOI: 10.1097/GOX.0000000000001075

Disclosure: The authors have no financial interest to declare in relation to the content of this article. The Article Processing Charge was paid for by the Department of Plastic Surgery, University of Texas Southwestern Medical Center.

Supplemental digital content is available for this article. Clickable URL citations appear in the text.

weakness to hypotension and tachycardia.^{15, 17} Application of topical nitroglycerin can provide quick improvement in tissue perfusion and often salvage questionably perfused tissue.

To determine when topical nitroglycerin would be efficacious, the senior author (B.A.) developed an algorithmic approach for the use of topical nitroglycerin integrated with SPY-Q analysis in tissue expander-based reconstructions.

Algorithm

An algorithmic approach to application of nitroglycerin paste and use of SPY was developed by the senior author (B.A.) based on the multisurgeon experience of 214 consecutive tissue expander cases over a 3 year period. Intraoperative measurement regarding the patients' overall clinical assessment was taken into consideration and the timing of topical nitroglycerin application with correspondence to the time lapsed after ICG injection was noted. Postoperative side effects and patient tolerance with topical nitroglycerin application were also considered. Ischemic tissue was then reassessed at 1- and 4-week postoperative intervals. Based on his clinical findings, the algorithm shown in Figure 1 was formed.

Whenever there is a concern for tissue ischemia and viability, SPY angiography is performed (Fig. 2) (See figure, Supplemental Digital Content 1, which displays a clinical exam of mastectomy flaps, <http://links.lww.com/PRSGO/A277>). If SPY-Q analysis shows >20% perfusion, no intervention is needed as this is adequate perfusion for tissue salvage based on manufacturer's recommendations.^{12, 18} If <20% perfusion, the area of decreased perfusion is evalu-

ated, and if the area of ischemia is >100cm² per breast breasts or the intraoperative systolic blood pressure is <120 mm Hg then topical nitroglycerin is held^{19, 20} (Fig. 3). Surgical interventions such as deflation or removal of the expander, trimming the ischemic mastectomy flap edge, or advancing the hyperperfused areas on the mastectomy flap to ensure tension-free closure are our primary management strategy.

If the area of decreased perfusion is <100cm² per breast and the patient's intraoperative systolic blood pressure is above 120mm Hg, we apply a layer of topical nitroglycerin to the ischemic area (Fig. 4). If the perfusion remains <20% after immediate repeat imaging with the remainder of the dye, then we proceed with the aforementioned surgical interventions. If the perfusion improves >20%, then we place patients on our topical nitroglycerin protocol for 7 days^{17, 20} applying it every 6 hours.

While on the topical nitroglycerin protocol, the patient is monitored for side effects. If the patient's blood pressure drops below 100 mm Hg or they develop intolerable headaches, then the topical nitroglycerin is diluted with bacitracin or other petroleum jelly-compatible ointment to a 50/50 mixture and reapplied 1 hour after removal of the topical nitroglycerin.

If the patient continues to have systolic blood pressures <100 mm Hg or other side effects, the mix is further diluted to 25% topical nitroglycerin and 75% bacitracin. This current regimen will be maintained for 7 days. If during this time the patient's blood pressure improves above 120 mm Hg, then full strength topical nitroglycerin will be applied.

We believe that the application of topical nitroglycerin has less systemic effects in mastectomy flaps due to their

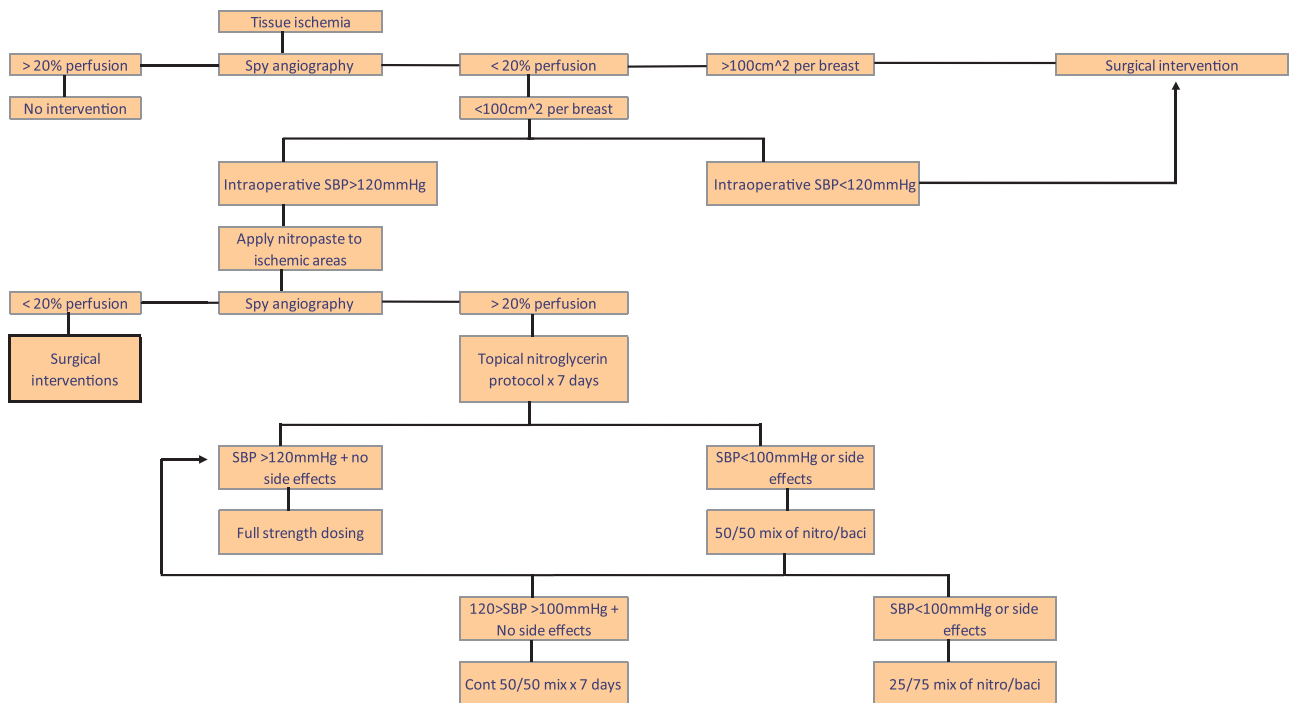


Fig. 1. Spy angiography algorithm.

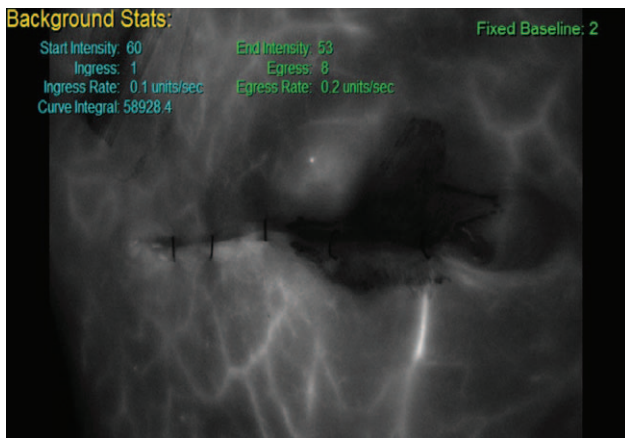


Fig. 2. Spy angiography before nitropaste application. Mastectomy skin flap with areas of decreased perfusion on SPY angiography.

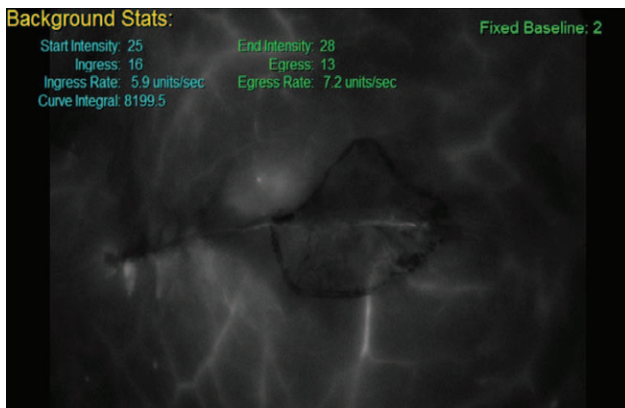


Fig. 3. SPY angiography after nitropaste application. Note the improved perfusion throughout the area that the nitropaste was applied.

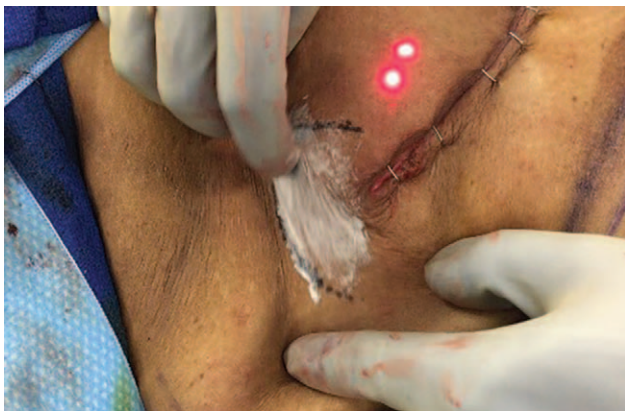

Fig. 4. Application of nitropaste to ischemic area identified with SPY angiography. No more than 2 packets (15 mg) of topical nitroglycerin is used. The nitropaste is applied and spread thin until a see-through layer is placed over the area of concern. The angiography is performed immediately before and after the application of nitropaste to evaluate for improvement in perfusion.

decreased perfusion. We do not advocate routine use of nitro paste in autologous reconstruction because the perfusion of the applied area is higher and a systemic drop in blood pressure can lead to flap loss.

In cases where intraoperative systemic hypertensive agents are utilized or the mastectomy was performed with epinephrine based tumescence, we will still use the above protocol; however, the reliability of the results is usually lower. Anecdotally, since the senior author (B.A.) started implementing this algorithm, he has significantly decreased unplanned surgical revisions to excise necrotic mastectomy flaps and early expander failures.

CONCLUSIONS

Compared with clinical judgment or other methods of tissue perfusion analysis, the advent of SPY angiography has made real-time intraoperative evaluation of tissue perfusion possible, which has provided objectivity to surgical decision making and correlated positively with clinical outcomes.¹⁻⁴ Topical nitroglycerin can salvage tissue with threatened vascularity; however, it is not without side effects (See figures, Supplemental Digital Content 2 and 3, which demonstrate 1- and 4-week postop photos, <http://links.lww.com/PRSGO/A278> and <http://links.lww.com/PRSGO/A279>). We developed a logical algorithmic approach based on integrating SPY angiography and topical nitroglycerin in a safe and effective method in the management of questionable tissue vascularity in patients with mastectomy. Although this is an ideas and innovations topic, this approach combines 2 elements (SPY angiography and nitropaste) that have been increasingly prevalent in the literature in regards to cost savings and efficacy. With the recent data supporting the cost savings of SPY and the importance of expedited wound healing before neoadjuvant therapies, we now recommend its use in all mastectomy flap cases at the discretion of the plastic surgeon when considering their own complication rate.

Bardia Amirlak, MD, FACS

Department of Plastic Surgery
University of Texas Southwestern Medical Center
1801 Inwood Road
Dallas, TX 75390
E-mail: Bardia.Amirlak@UTSouthwestern.edu

REFERENCES

1. Komorowska-Timek E, Gurtner GC. Intraoperative perfusion mapping with laser-assisted indocyanine green imaging can predict and prevent complications in immediate breast reconstruction. *Plast Reconstr Surg.* 2010;125:1065-1073.
2. Phillips BT, Lanier ST, Conkling N, et al. Intraoperative perfusion techniques can accurately predict mastectomy skin flap necrosis in breast reconstruction: results of a prospective trial. *Plast Reconstr Surg.* 2012;129:778e-788e.
3. Duggal CS, Madni T, Losken A. An outcome analysis of intraoperative angiography for postmastectomy breast reconstruction. *Aesthet Surg J.* 2014;34:61-65.
4. Phillips BT, Fourman MS, Rivara A, et al. Comparing quantitative values of two generations of laser-assisted indocyanine green dye angiography systems: can we predict necrosis? *Eplasty* 2014;14:e44.
5. Gdalevitch P, Van Laeken N, Bahng S, et al. Effects of nitroglycerin ointment on mastectomy flap necrosis in immediate breast reconstruction: a randomized controlled trial. *Plast Reconstr Surg.* 2015;135:1530-1539.

6. Green JM 3rd, Thomas S, Sabino J, et al. Use of intraoperative fluorescent angiography to assess and optimize free tissue transfer in head and neck reconstruction. *J Oral Maxillofac Surg.* 2013;71:1439–1449.
7. Gurtner GC, Jones GE, Neligan PC, et al. Intraoperative laser angiography using the SPY system: review of the literature and recommendations for use. *Ann Surg Innov Res.* 2013;7:1.
8. Alander JT, Kaartinen I, Laakso A, et al. A review of indocyanine green fluorescent imaging in surgery. *Int J Biomed Imaging.* 2012;2012:940585.
9. Hope-Ross M, Yannuzzi LA, Gragoudas ES, et al. Adverse reactions due to indocyanine green. *Ophthalmology* 1994;101:529–533.
10. Benya R, Quintana J, Brundage B. Adverse reactions to indocyanine green: a case report and a review of the literature. *Cathet Cardiovasc Diagn.* 1989;17:231–233.
11. Kanuri A, Liu AS, Guo L. Whom should we SPY? A cost analysis of laser-assisted indocyanine green angiography in prevention of mastectomy skin flap necrosis during prosthesis-based breast reconstruction. *Plast Reconstr Surg.* 2014;133:448e–454e.
12. Jacobson S. SPY fluorescence imaging the transformation of information. Presented at the ISPIES Summit, Las Vegas, September 26, 2015.
13. Chatterjee A, Krishnan NM, Van Vliet MM, et al. A comparison of free autologous breast reconstruction with and without the use of laser-assisted indocyanine green angiography: a cost-effectiveness analysis. *Plast Reconstr Surg.* 2013;131:693e–701e.
14. Davis RE, Wachholz JH, Jassir D, et al. Comparison of topical anti-ischemic agents in the salvage of failing random-pattern skin flaps in rats. *Arch Facial Plast Surg.* 1999;1:27–32.
15. Kutun S, Ay AA, Ulucanlar H, et al. Is transdermal nitroglycerin application effective in preventing and healing flap ischaemia after modified radical mastectomy? *S Afr J Surg.* 2010;48:119–121.
16. Munabi NC, Olorunnipa OB, Goltzman D, et al. The ability of intra-operative perfusion mapping with laser-assisted indocyanine green angiography to predict mastectomy flap necrosis in breast reconstruction: a prospective trial. *J Plast Reconstr Aesthet Surg.* 2014;67:449–455.
17. Rohrich RJ, Cherry GW, Spira M. Enhancement of skin-flap survival using nitroglycerin ointment. *Plast Reconstr Surg.* 1984;73:943–948.
18. Gurtner GC. Using SPY to prevent complications in ablative and reconstructive breast surgery. Presented at the ISPIES Summit, Las Vegas, September 25, 2015.
19. The Collaborative Investigation Group. A comparative evaluation of two transdermal nitroglycerin delivery systems: Nitro-Dur versus Transderm-Nitro. *Clin Ther.* 1991;13:545–549.
20. Jimenez ER, Whitney-Caglia L. Treatment of chronic lower extremity wound pain with nitroglycerin ointment. *J Wound Ostomy Continence Nurs.* 2012;39:649–652.